

Aripiprazole Induced Non-Cardiogenic Pulmonary Edema: A Case Report



Mustafa ÇETİN¹, Mustafa ÇELİK², Musa ÇAKICI³, Mustafa POLAT⁴, Arif SUNER⁵

SUMMARY

Aripiprazole is a second-generation antipsychotic drug with partial dopamine agonistic activity. Although the adverse cardiovascular effects of both typical and atypical antipsychotics are well known, similar data on aripiprazole, which was recently introduced, are scarce. Herein we report a 35-year-old female that presented to our emergency department with non-cardiogenic pulmonary edema. Chest X-ray and thoracic CT showed pulmonary edema and bilateral pleural effusion. Anamnesis showed that she had been taking sertraline 200 mg d⁻¹ for obsessive-compulsive disorder for a long time and that aripiprazole 10 mg d⁻¹ was added for augmentation 2 months prior to presentation. We think that the CYP 2D6 inhibitor sertraline might have played a role in increasing the plasma concentration and toxicity of aripiprazole in the presented patient.

Keywords: Aripiprazole, pulmonary edema, CYP2D6

INTRODUCTION

Aripiprazole is a second-generation antipsychotic with anti-depressant properties that is used to treat many psychiatric disorders, including schizophrenia, bipolar disorder, major depressive disorder, and anxiety disorders (Worthington et al. 2005). Both typical and atypical antipsychotic drugs can cause adverse cardiovascular effects, even when administered at typical treatment doses. Such adverse effects include orthostatic hypotension, myocarditis, arrhythmias, cardiomyopathy, and sudden death (Harrison et al. 2005). Herein we present what to the best of our knowledge is the first case of non-cardiogenic pulmonary edema associated with aripiprazole.

CASE

A 35-year-old female presented to the emergency department of Adiyaman University Research and Education Hospital, Adiyaman, Turkey, with breathing difficulty. At the time of presentation she had central cyanosis. Respiratory system

examination showed rales beginning at the midfield of each lung. Orthopnea was significant. Blood pressure was 100/70 mmHg. Oxygen saturation measured from her finger was 80%. Normal sinus rhythm was noted via electrocardiography and her heart rate was 110 bpm. Chest X-ray and thoracic CT showed pulmonary edema and bilateral pulmonary effusion (Figures 1 and 2). Urea, creatinine, albumin, thyroid function tests, liver function tests, white blood cell count, creatinine kinase MB, and cardiac troponin levels were within normal limits. Cardiac chamber volume, cardiac valve morphology, and the ejection fraction were normal. Based on these findings, the patient was diagnosed as non-cardiogenic pulmonary edema.

The patient's psychiatric history included obsessive-compulsive symptoms for the last 5 years. Due to obsessions of contamination and doubt, and compulsions of cleaning and control, sertraline was started and increased to 200 mg d⁻¹, and then aripiprazole 10 mg d⁻¹ was added 2 months before presentation to the emergency department. The patient was admitted to the coronary intensive care unit. Sertraline and

Received: 03.03.2013 - Accepted: 25.07.2013

^{1,3,4,5}MD/Assist. Prof., Adiyaman University, School of Medicine, Cardiology, 2MD/Assist. Prof., Adiyaman University, School of Medicine, Psychiatry, Adiyaman.

e-mail: mustacelik@yahoo.com

aripiprazole were withdrawn, and continuous positive airway pressure (CPAP) treatment was initiated. Furosemide infusion and prednisolone were administered. At first day of hospitalization urine flow of 6000 mL was achieved and symptomatic improvement was observed. The patient was discharged with complete remission after 5 d of hospitalization, and 3 months post discharge no cardiologic problem was observed. At the time this manuscript was prepared the patient was being followed-up with citalopram 40 mg d⁻¹ for obsessive-compulsive disorder (OCD).

DISCUSSION

Aripiprazole is a relatively new atypical antipsychotic with a mechanism of action that differs from that of other antipsychotics. It acts both on postsynaptic dopamine D2 receptors and presynaptic autoreceptors, and it is a partial dopamine agonist (Bolonna et al. 2005; Travis et al. 2005). The molecule was first studied in schizophrenia patients and was reported to be effective for the positive, negative, and extrapyramidal symptoms of schizophrenia (DeLeon et al. 2004). There are some case reports on aripiprazole use for augmentation in treatment-resistant OCD patients (Ozturk and Coskun 2009; Fornaro et al. 2008; Sarkar et al. 2008; Storch et al. 2008;). Two open-label studies by Pessina et al. (2009) and Ak et al. (2011), and a double blind, randomized placebo controlled study by Muscatello et al. (2011) showed that aripiprazole augmentation of serotonin reuptake inhibitors effectively reduced the symptoms of OCD.

Non-cardiogenic pulmonary edema is also known as acute respiratory distress syndrome (ARDS) (Bernard et al. 1994). Although the pathophysiological mechanism of non-cardiogenic pulmonary edema is not fully known, it is thought to be due to capillary endothelial damage and increased escape of proteins due to an increase in vascular permeability, which causes deposition of protein-rich fluid in alveolar air sacs and formation of hyaline membranes rich in fibrin and other proteins (Bernard et al. 1994). Although it is known that such antipsychotic drugs as phenothiazines, droperidol, and pericyazine can induce pulmonary edema, there is limited direct evidence of such an association (Wilson and Ridley 2007; Sorianno et al. 2003; Ozkan et al. 2001; Savici et al. 2001; Dahlin et al. 1997; Li and Gefter. 1992; Johnson et al. 1988). Although the pathophysiological mechanism is not precisely defined in these earlier studies, a dose-dependent effect (Dahlin et al. 1997), a part of neuroleptic malignant syndrome (Sorianno et al. 2003; Johnson et al. 1988), neurogenic pulmonary edema (Li and Gefter 1992), and an allergic reaction involving neutrophil activation in many tissues, including lung tissue (Savici et al. 2001), have been proposed. Based on reported cases, neurogenic pulmonary edema due to dopamine blockage in basal ganglia and the hypothalamus

appears to be a plausible mechanism (Wilson and Ridley 2007; Li and Gefter 1992). In the presented case the side effects of aripiprazole toxicity, including dyspnea, palpitations, chest pain, and nausea, were noted, but orthostatic hypotension, drowsiness, and akathisia might have been masked due to irritability and the need to sit down because of orthopnea.

The adverse cardiovascular effects of antipsychotic drugs have recently been studied more extensively (Michelsen and Meyer 2007). Orthostatic hypotension, myocarditis, cardiac conduction defects, left ventricular dysfunction, and arrhythmias (including torsades de pointes and ventricular fibrillation) are among such adverse effects, which have also been reported to be associated with sudden cardiac death (Harrison et al. 2005). To the best of our knowledge the literature does include any cases of aripiprazole-induced non-cardiogenic pulmonary edema, but there are 21 cases of pulmonary edema in adverse effect reports to the US Food and Drug Administration (FDA) (www.ehealthme.com), 5 of which were diagnosed as depression and 5 as anxiety disorders; 5 of these patients were using fluoxetine, 3 were using venlafaxine, 2 were using sertraline, and 1 was using paroxetine and aripiprazole. In 62.5% of these cases non-cardiogenic pulmonary edema occurred within 6 months of starting aripiprazole (www.ehealthme.com). The presented case was using sertraline for a long period and aripiprazole for augmentation was added 2 months prior to presentation.

As aripiprazole is primarily metabolized by microsomal enzymes CYP450 3A4 and 2D6, its plasma concentration increases when used together with inhibitors of these enzymes. The aripiprazole level increases when it is used in combination with potent CYP450/2D6 inhibitors, such as ketoconazole and quinidine (DeLeon et al. 2004); therefore, Travis et al. recommend adjusting the aripiprazole dose when it is combined with fluoxetine or paroxetine (Travis et al. 2005). Sertraline also inhibits CYP2D6 (Spina et al. 2008; Nemeroff et al. 1996). A study in which sertraline was added to risperidone reported that the plasma risperidone concentration didn't change in 9 patients that took sertraline 50-100 mg d⁻¹, but increased by 36% and 52% in 2 patients that took sertraline 150 mg d⁻¹ (Spina et al. 2004). In the presented patient the high dose of sertraline (200 mg d⁻¹) might have increased the plasma aripiprazole concentration via inhibition of CYP/2D6.

In conclusion, although it is not possible to state with certainty that aripiprazole caused non-cardiogenic pulmonary edema in the presented patient, we recommend caution when introducing CYP3A4 and/or 2D6 inhibitors to patients currently using aripiprazole. Amid the increase in the use of aripiprazole augmentation in the treatment of mood and anxiety disorders, it is important to develop guidelines that include dose adjustments for preventing unfavorable drug-drug interactions.

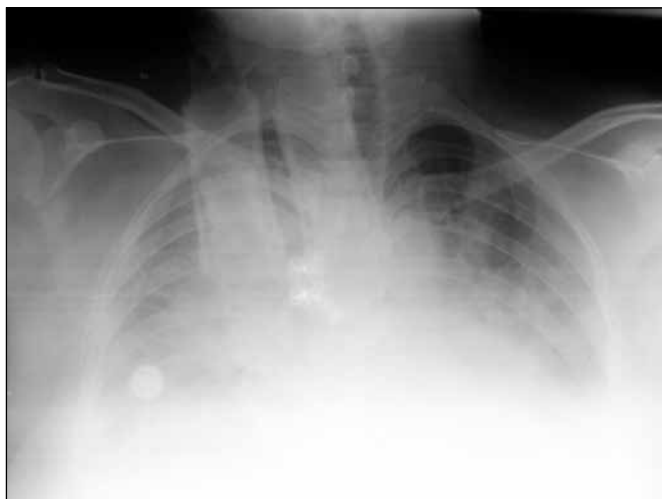


Figure 1. Chest X-ray at admission shows bilateral opacity in the lower and middle lung zones.

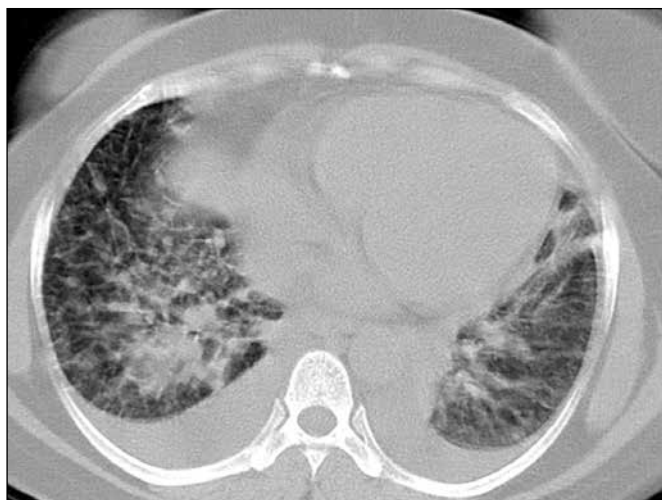

Figure 2. CT scan shows bilateral pleural effusion in the lower lung zones, areas of consolidation, and ground-glass opacity.

REFERENCES

- Ak M, Bulut SD, Bozkurt A et al (2011) Aripiprazole augmentation of serotonin reuptake inhibitors in treatment-resistant obsessive-compulsive disorder: a 10-week open-label study. *Adv Ther.* 28:341-8
- Bernard GR, Artigas A, Brigham KL et al (1994) The American-European Consensus Conference on ARDS: definitions, mechanisms, relevant outcomes, and clinical trial coordination. *Am J Respir Crit Care Med* 149:818.
- Bolonna AA, Kerwin RW (2005) Partial agonism and schizophrenia. *Br J Psychiatry* 186:7-10.
- Dahlin KL, Lastbom L, Blomgren B et al (1997) Acute lung failure induced by tricyclic antidepressants. *Toxicol Appl Pharmacol* 146:209-16.
- DeLeon A, Patel NC, Crismon ML (2004) Aripiprazole: a comprehensive review of its pharmacology, clinical efficacy, and tolerability. *Clin Ther* 26:649-66.
- Fornaro M, Gabrielli F, Mattei C et al (2008) Aripiprazole augmentation in poor insight obsessive-compulsive disorder: a case report. *Ann Gen Psychiatry.* 23:26.
- Harrison TR, Fauci A, Braunwald E, et al (2005) *Harrison's Internal Medicine.* Sixteen Edition. New York: McGraw-Hill, s 1532-5.
- Johnson MD, Newman JH, Baxter JW (1988) Neuroleptic malignant syndrome presenting as adult respiratory distress syndrome and disseminated intravascular coagulation. *South Med J* 81:543-5.
- Li C, Geftter BW (1992) Acute pulmonary oedema induced by overdosage of phenothiazines. *Chest* 101:102-4.
- Michelsen JW, Meyer JM (2007) Cardiovascular effects of antipsychotics. *Expert Rev Neurother.* 7:829-39.
- Muscattello MR, Bruno A, Pandolfo G et al (2011) Effect of aripiprazole augmentation of serotonin reuptake inhibitors or clomipramine in treatment-resistant obsessive-compulsive disorder: a double-blind, placebo-controlled study. *J Clin Psychopharmacol.* 31:174-9
- Nemeroff CB, DeVane CL, Pollock BG (1996) Newer antidepressants and the cytochrome P450 system. *Am J Psychiatry* 153:311-20.
- Ozkan M, Dweik RA, Ahmad M (2001) Drug-induced lung disease. *Cleve Clin J Med.* 68:782-5, 789-95.
- Ozturk M, Coskun M (2009) Successful aripiprazole augmentation in a child with drug-resistant obsessive-compulsive disorder. *J Clin Psychopharmacol.* 29:607-9.
- Pessina E, Albert U, Bogetto F et al (2009) Aripiprazole augmentation of serotonin reuptake inhibitors in treatment-resistant obsessive-compulsive disorder: a 12-week open-label preliminary study. *Int Clin Psychopharmacology.* 24:265-9.
- Sarkar R, Klein J, Kruger S (2008) Aripiprazole augmentation in treatment-refractory obsessive-compulsive disorder. *Psychopharmacology (Berl).* 197:687-8,30.
- Savici D, Katzenstein A-L (2001) Diffuse alveolar damage and recurrent respiratory failure report of 6 cases. *Hum Pathol* 32:1398-402.
- Spina E, D'Arrigo C, Migliardi G et al (2004) Plasma risperidone concentrations during combined treatment with sertraline. *Ther Drug Monit.* 26:386-90.
- Spina E, Santoro V, D'Arrigo C (2008) Clinically relevant pharmacokinetic drug interactions with second-generation antidepressants: an update. *Clin Ther.* 30:1206-27.
- Sorianno FG, Vianna Edos S, Velasco IT (2003) Neuroleptic induced acute respiratory distress syndrome. *Sao Paulo Med J* 121:121-4.
- Storch EA, Lehmkuhl H, Geffken GR et al (2008) Aripiprazole augmentation of incomplete treatment response in an adolescent male with obsessive-compulsive disorder. *Depress Anxiety.* 25:172-4.
- Travis MJ, Burns T, Dursun S et al (2005) Aripiprazole in schizophrenia: consensus guidelines. *Int J Clin Pract* 59:485-95.
- Wilson H, Ridley S (2007) Antipsychotic drugs and the acute respiratory distress syndrome. *Br J Anaesth.* 99:301-2
- Worthington JJ 3rd, Kinrys G, Wygant LE et al (2005) Aripiprazole as an augmentor of selective serotonin reuptake inhibitors in depression and anxiety disorder patients. *Int Clin Psychopharmacol.* 20:9-11.
- www.eHealthMe.com. real world drug outcomes. Could Abilify cause Non-cardiogenic pulmonary edema? A study of 21 users. Available from:URL: <http://www.ehealthme.com/ds/abilify/non-cardiogenic+pulmonary+edema>. Last Access date: 01-03-2013.