

Comparison of Cerebral Blood Flow in Children with Obsessive Compulsive Disorder and Attention Deficit Hyperactivity Disorder

Pınar ÖNER, Özgür ÖNER, Ayla AYSEV, Özlem KÜÇÜK, Erkan İBİŞ

Abstract

Objective: It has been reported that both obsessive-compulsive disorder (OCD) and attention deficit hyperactivity disorder (ADHD) might be related to impairments in frontal-striatal brain circuits. Besides, these two disorders are frequently comorbid. However, there are no published studies directly comparing the neurobiological findings in these two disorders. The objective of the study was to investigate the differences in cortical blood flow between patients with OCD and ADHD.

Method: Thirteen drug-naive OCD subjects (mean age \pm SD: 10.4 \pm 2.8), and 13 drug-naive ADHD subjects (mean age \pm SD: 10.5 \pm 2.2) were included in the study. Cerebral blood flow (CBF) was evaluated with Tc-99m-hexamethylpropyleneamine oxime (Tc^{99m} HMPAO) brain single photon emission tomography (SPECT) during standard resting conditions in all cases. P value was set to <.006 after Bonferroni correction.

Results: OCD cases had significantly higher right prefrontal ($p=.003$) CBF than ADHD cases. There were no significant CBF differences in other brain regions. OCD symptom severity was not related to CBF.

Discussion: This is one of the very few studies which directly investigated brain imaging in pediatric OCD subjects. Results are consistent with previous studies reporting increased prefrontal CBF in OCD subjects. We also found that, consistent with the previous literature, ADHD subjects had lower prefrontal cortex CBF. Studies which compare subjects with comorbid ADHD and OCD with pure forms of these disorders are necessary to have a better understanding of similarities and differences of these two disorders.

Key Words: OCD, ADHD, SPECT, prefrontal cortex

INTRODUCTION

First symptoms of Obsessive Compulsive Disorder (OCD) occur before the age of 15 in one-third to one-half of the adults with this disorder (Pauls et al. 1995). Neurological findings suggest basal ganglia dysfunction is more common in children and adolescents with OCD (Rosenberg and Keshavan 1998). OCD is believed to be a neurodevelopmental disorder rather than a degenerative process and this illustrates the importance of research on pediatric and adolescent OCD cases (Rosenberg and Keshavan 1998). Childhood-onset OCD may hold important clues for the etiology of the adult-onset disorder.

Changes in cortical blood flow, metabolism and activation have been shown in OCD cases using Single Photon Emission Tomography (SPECT), Positron

Emission Tomography (PET) and functional Magnetic Resonance Imaging (fMRI) (Aouizerate et al. 2004). These changes are most consistent in the prefrontal and anterior cingulate cortices and the head of caudate nucleus. On the other hand, changes have been demonstrated in children and adolescent cases by structural neuroimaging techniques (Giedd et al. 2000, Gilbert et al. 2000). Functional neuroimaging studies have been carried out in adult OCD cases with childhood-onset (Swedo et al. 1992, Busatto et al. 2000) while those on pediatric and adolescent OCD cases are scarce. Diler and colleagues' study on pediatric and adolescent OCD cases showed bilateral increase in blood flow to the caudate nucleus, prefrontal and cingulate cortices (2004). Another study observed no changes cerebral blood flow after clomipramine treatment in 10 pediatric and adolescent OCD cases but reported a negative relation be-

Acknowledgment: This study is funded by the Ankara University Research Fund (Pınar Öner, Project number: 201-08-09-045). Further, during the writing of this manuscript, the study was also supported by the grant from the NIMH Fogarty International Mental Health and Developmental Disabilities Research Training Program to Kerim Munir (D43TW05807).
Pınar Öner MD., e-mail: pinaryoner@yahoo.com

tween the age at the onset of the disorder and calendar age with the frontal and parietal blood flow bilaterally (Castillo et al. 2005).

Attention Deficit Hyperactivity Disorder (ADHD) is another neurodevelopmental disorder. Functional imaging studies showed decreases in prefrontal, parietal, anterior cingulate cortices and caudate nucleus blood flows and a decrease in metabolic activity (Bush et al. 2005). Results of many structural cerebral imaging studies suggest that right prefrontal-basal ganglia anomalies underlie ADHD pathophysiology (Castellanos 1997).

It has been proposed that OCD is a hyperglutamatergic and ADHD is a hypoglutamatergic condition, with prefrontal brain regions being especially affected (Carlsson 2000). According to some researchers, abnormalities in the cortico-striato-thalamo-cortical (CSTC) pathways are alike: ADHD, OCD and Tourette's syndrome represent inhibition in the indirect CSTC pathways or hyperactivation in the direct pathway (Baxter et al. 1992, Aouizerate et al. 2004). Moreover, co-existence of these disorders lends support to this idea. Therefore, direct comparison of OCD and ADHD cases could yield some interesting data.

Primary aim of this study was to make a contribution to the functional imaging studies on pediatric and adolescent OCD cases. In the light of previous studies, we hypothesized that prefrontal blood flow in pediatric and adolescent OCD cases is higher than that of ADHD cases.

METHOD

Sample

Sample included 13 OCD (4 males, 9 females) and 13 ADHD (8 males, 5 females) cases. ADHD cases were selected from 29 ADHD cases on which age related changes in cerebral blood flow (CBF) was investigated (Öner et al., 2005). To control for age and sex variables, ADHD and OCD cases were matched so that there would be no significant age or sex differences. For this matching, all female ADHD cases were selected and age-matched in a range of ± 1 years. All cases selected matching fulfilled the inclusion criteria. When there was a possibility of more than one matching, the one who applied first was included in the study. None of the subjects were left-handed based on the laterality inventory of the Pediatric Neurological Examination for Subtle Signs (Denckla, 1985). All OCD and ADHD cases were selected among consecutive patients who presented to the

Child Psychiatry Outpatient Clinic of a university hospital and fulfilled the inclusion criteria. Informed consent was obtained from the families and the University Ethics Committee approved the study. Diagnoses were made by two psychiatrists based on diagnostic criteria set forth in DSM-IV and there was a perfect agreement in the diagnoses by both psychiatrists. Medical histories of all OCD and ADHD cases were normal and they were screened clinically for psychosis, eating disorder, substance abuse, mental retardation and diffuse developmental disorders. None of the cases had prior treatment. Concomitant ADHD or chronic tic disorder was not identified in any of the OCD cases. Inclusion criteria for the subjects included having OCD or ADHD based on DSM-IV diagnostic criteria, absence of any other medical condition in the history, and be between 7-14 years of age. Psychosis, eating disorder, substance abuse, mental retardation, pervasive developmental disorder, presence of concomitant tic and ADHD in an OCD patient and incomppliance to SPECT (excessive movement, excessive crying, resistance to injection, etc) comprised the exclusion criteria. Three OCD and two ADHD cases were excluded from the study.

Assessment tools

Conners' Teacher Rating Scale (CTRS): Comprised of 28 items, this scale is used by teachers to rate the behavior of children at school (Goyette 1978). Eight items comprise inattention, 7 items comprise hyperactivity and 8 items comprise conduct problems subscale. Validity and reliability of the Turkish version of the scale is satisfactory (Cronbach alpha .95) (Şener et al. 1995).

Children Yale-Brown Obsessive Compulsive Scale (CY-BOCS): CY-BOCS is a 10-item scale that is scored by a clinician. Assessment takes 10 minutes on average. It is a semi-structured tool to measure the severity of OCD signs within the past week. There are five major sections: (1) Instructions, (2) obsession screening list, (3) items to determine the severity of obsessions, (4) compulsion screening list, (5) items to determine the severity of compulsions. Information gathered from the child and his/her parents are used for scoring. The obsession and compulsion subtotal scores are the sums of items 1-5 and 6-10, respectively. Compared to the adults, more time should be allocated for children during the first administration and, depending on the level of development, obsessions and compulsion should be explained with different terms. CY-BOCS is designed to be administered to children aged between 8 and 16. It has been shown that it is valid and reliable for children (Scahill

Table 1. Regional Cerebral blood flow (CBF) measurements normalized for total cortical blood flow (sum of bilateral prefrontal, frontal, parietal and temporal cortical CBF) in OCD and ADHD cases. Mann-Whitney-U test. * Significant differences after Bonferroni correction.

Regions of interest	OCD (n=13) Mean±SD	ADHD (n=13) Mean±SD	z	p
Right Prefrontal	,141±.003	,121±.001	2.89	.003*
Left Prefrontal	,115±.002	,125±001	1.82	.069
Right Frontal	,120±.002	,121±001	.18	.858
Left Frontal	,111±003	,125±001	1.51	.130
Right Parietal	,126±001	,124±001	1.56	.118
Left Parietal	,106±003	,125±001	1.56	.118
Right Temporal	,136±002	,127±001	.128	.920
Left Temporal	,144±003	,132±001	.555	.590

et al. 1997). Adaptation to Turkish language as well as validity and reliability studies has been carried out by Yücelen and colleagues (2000).

PROCEDURE

Image acquisition

All children and their families were informed about the procedure. Before the image acquisition, subjects lay in the supine position with their eyes closed for minimal sensorial stimuli for five minutes. Subjects were then administered intravenous Tc^{99m} HMPAO in the presence of a parent. The dose of Tc^{99m} HMPAO was calculated separately for each subject using the formula [(age+1)/(age+7)] x standard adult dose (15 mci). Subjects rested until SPECT images were acquired, 15 minutes after the injection. Each subject was checked by the researchers for compliance to the procedure and three OCD and two ADHD cases were excluded from the study.

Radiochemical purity was determined by chromatography and was found above 90% each time. Images were acquired with a SPECT system (GE 4000I) equipped with a high-resolution collimator and each SPECT image was recorded on 128 projections on a 64 x 64-matrix, giving a pixel size of 4 mm, with a total acquisition time of 3 minutes. Data was processed using a Meltz filter, images were reconstructed with filtered back-projection algorithm with a ramp filter, and data was corrected with Sorenson method. Oblique reorientation was used to obtain transaxial slices of 2 pixels (8 mm) thickness parallel to the orbitomeatal line.

Regions of interest (ROI) were manually traced in

the right prefrontal, frontal, temporal and parietal cortices. ROI analyses were performed by one of the authors (Dr ÖK) blind to the diagnoses of the subjects. To increase the objectivity of the findings, the procedures were repeated with known clinical parameters (O'Tauma et al. 1999).

A neuroanatomy atlas was used to choose different regions on transaxial sections. Semi-quantitative analyses were performed on five consecutive oblique slices corresponding to anatomical planes. It is possible that the cerebellum plays a part in the pathophysiology of ADHD. Therefore, in contrast to many previous studies, we expressed the ratio of ligand uptake in the regions of interest to the cortical blood flow (sum of cerebral blood flows to the prefrontal, frontal, parietal and temporal cortices bilaterally) for each subject for "normalization".

Data analyses

Non-parametric Mann-Whitney-U test was used to determine the significance of differences in cerebral blood flow (CBF) between groups. Bonferroni method was used to control for multiple comparisons and adjusted p=.006 (0.05/8, the number of regions of interest; right and left prefrontal, frontal, temporal and parietal) was considered statistically significant. SPSS v10.0 statistical package was used for analyses.

FINDINGS

Age and Sex

There was no significant sex difference between groups ($\chi^2=2.4$, $p>.23$). Age distribution did not sig-

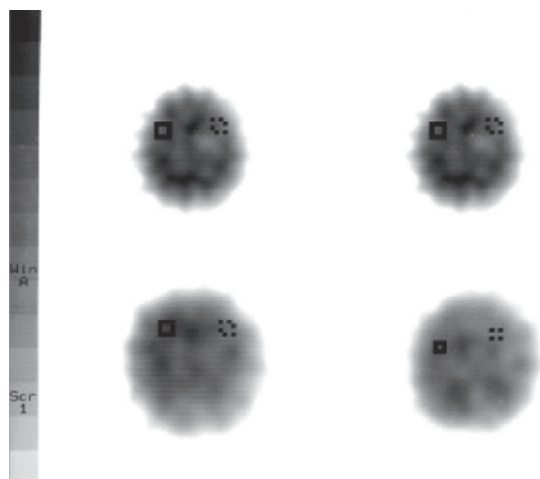


Figure 1. Regions of interest in obsessive compulsive disorder and attention deficit and hyperactivity disorder cases. OCD cases are on the right side of the panel and ADHD cases are on the left side of the panel. Upper half of the panel depicts right and left prefrontal regions while lower half of the panel shows the right and left parietal regions of interest.

nificantly differ between groups either (mean age \pm SD for OCD: 10.4 \pm 2.8 years; mean age \pm SD for ADHD= 10.5 \pm 2.2 years; $z=-.52$, $p=.96$).

Severity of Symptoms

CY-BOCS was used to measure the severity of symptoms in the OCD group (range: 0-40, obsessive symptoms, mean=11.2, SD =4.1; compulsive symptoms, mean=12.9, SD=3.5). ADHD symptom severity was measured by CTRS (Inattention, mean =8.8, SD =4.2, Hyperactivity, mean =11.9, SD =3.7, Conduct problems, mean =9.0, SD =4.2, Total, mean =34.0, SD =8.5).

SPECT Examination

“Normalized” CBF measurements of the groups are summarized in Table I.

Mann-Whitney-U test results showed that CBF in the right prefrontal region of OCD cases was significantly higher than ADHD cases ($z=2.89$, $p=.003$). Differences in CBFs in other regions between groups were not statistically significant after Bonferroni correction.

No significant relation was observed between OCD severity and CBF measurements.

DISCUSSION

This study is one of the few studies that examined child and adolescent OCD cases directly. Results showed

that normalized CBF in the right prefrontal cortex in OCD cases was higher than ADHD cases.

Results of the present study are consistent with those of ADHD- and OCD-related studies. Many functional neuroimaging studies demonstrated increases in prefrontal metabolism and blood flow in OCD cases (Aouizerate et al. 2004). A SPECT study on children and adolescents lends support to this finding (Diler et al. 2004). One other study found relations between current age and the age at the onset of the disorder with bilateral frontal blood flow in children and adolescents (Castillo et al. 2005). Some other neuroimaging studies showed an association between improvement in symptoms and restoration of prefrontal cortical metabolism or blood flow (Baxter et al. 1992, Swedo et al, 1992, Benkelfat et al. 1990, Perani et al. 1995, Saxena et al. 1999). On the other hand, there exist studies that failed to find an increase in prefrontal activity (Crespo-Facorro et al. 1999, Busatto et al. 2000). Our findings demonstrated an increase in prefrontal cortical activity in children and adolescents with OCD, similar to the adult OCD cases. Many authors argued that, in OCD, there is a hyperfunction of the neural network comprised of prefrontal cortex, cingulate cortex and the head of the caudate nucleus (Insel 1992, Baxter 1994). In the present study, we found that right prefrontal blood flow in ADHD cases was lower than OCD cases. Many of the previous studies reported a decrease in activity in the right prefrontal region in ADHD cases (Zametkin et al. 1990, Zametkin et al. 1993, Rubia et al. 2000, Spalletta et al. 2001). With regard to this, the results of the present study are in agreement with those of the previous studies on these two disorders.

According to Bradshaw and Shephard, ADHD, OCD, autism and schizophrenia can be classified as “neurodevelopmental fronto-striatal disorders”. In addition to the possibility of diagnostic superposition, these disorders are highly comorbid and alterations in brain lateralization have been shown in all these disorders (Bradshaw and Shepard 2000). The authors argued that genetic and environmental factors acting on anatomically- or neurochemically-defined certain networks determine if and which disorder will occur. In other words, OCD and ADHD may be two disorders that are related to similar neural networks. Though they are in the same group, different sites in the fronto-striatal region are involved due to different genetic and environmental factors. Our findings showed that prefrontal CBF was higher in OCD cases than ADHD cases. Pathophysiology of these disorders can be better understood by examining cases with two disorders.

It is obvious that this study has certain limitations. The most important of these limitations is the lack of a control group comprised of healthy subjects. Even though results of the present study are consistent with previous studies, this complicates the interpretation of the results. However, there are ethical issues related to the use of SPECT in healthy children, a technique that utilizes ionizing radiation and many previous studies faced with the similar constraints (Bush et al. 2005). In a review by Bush and colleagues, the authors reported that of the 13 SPECT studies on ADHD cases, only three studies had a control group, the biggest of which was composed of 7 subjects. Four studies did not have a control group at all and the remaining six studies used psychiatric cases, neurological cases or siblings as controls (Bush et al. 2005). In one of the two studies on children and adolescents with OCD had no control group (Castillo et al. 2005). Considering the possible alterations in CBF, using subjects with other psychiatric or neurological disorders as a control group does not seem to be a good approach. Inclusion of siblings in the control group is problematic due to genetic predispositions that might affect CBF as well as ethical issues. This shows that all control, or comparison groups, to be more accurate, can introduce confounders and none of those choices serve as an ideal control group.

REFERENCES

- Aouizerate B, Guehl D, Cuny E, et al. (2004) Pathophysiology of obsessive-compulsive disorder: a necessary link between phenomenology, neuropsychology, imagery and physiology. *Prog Neurobiol*, 72:195-221.
- Baxter LJ, Schwartz JM, Bergman KS, et al. (1992) Caudate glucose metabolic rate changes with both drug and behavior therapy for obsessive-compulsive disorder. *Arch Gen Psychiatry*, 49:681-689.
- Baxter LR (1994) Positron emission tomography studies of cerebral glucose metabolism in obsessive-compulsive disorder. *J Clin Psychiatry*, 55:54-59.
- Benkelfat C, Nordahl TE, Semple WE, et al. (1990) Local cerebral glucose metabolic rates in obsessive-compulsive disorder, patients treated with clomipramine. *Arch Gen Psychiatry*, 47:840-48.
- Bradshaw JL, Shepard DM (2000) The neurodevelopmental frontostriatal disorders, evolutionary adaptiveness and anomalous lateralization. *Brain Lang*, 73: 297-320.
- Busatto GF, Zamignani DR, Buchpiguel CA, et al. (2000) A voxel-based investigation of regional cerebral blood flow abnormalities in obsessive-compulsive disorder using single photon emission computed tomography (SPECT) *Psychiatry Res*, 99:15-27.
- Bush G, Valera EM, Seidman LJ (2005) Functional neuroimaging of attention deficit hyperactivity disorder: a review and suggested future directions. *Biol Psychiatry*, 57:1273-84.
- Carlsson ML (2000) On the role of cortical glutamate in obsessive-compulsive disorder and attention deficit hyperactivity disorder, two phenomenologically antithetical conditions. *Acta Psychiatr Scand*, 102: 401-413.
- Castellanos FX (1997) Toward a pathophysiology of attention deficit hyperactivity disorder. *Clin Pediatrics*, 36:381-393.

Another limitation of the study is the fact that there was a sex difference between groups though it was not statistically significant. Previous PET studies have demonstrated a sex difference in brain metabolism in ADHD cases and suggested that this difference could be more pronounced in adult females (Zametkin et al. 1993, Ernst et al. 1994).

Sample size in studies that examined ADHD cases with SPECT varied between 8 and 54, with a mean of 22.9 (Bush et al. 2005). There are two previously published studies that assessed pediatric OCD cases and these studies included 18 and 14 OCD cases with no control subjects in the second study (Diler et al. 2004, Castillo et al. 2005). This suggests that sample size of ADHD and OCD cases in the present study is sufficient. We tried to minimize possible statistical errors by using non-parametric statistical tests and Bonferroni correction for multiple comparisons.

Despite these limitations, we believe the results of the present study that compared two disorders that might occur concomitantly and thought to be mediated by the same neural networks would be useful.

Castillo AR, Buchpiguel CA, de Araujo LA et al. (2005) Brain SPECT imaging in children and adolescents with obsessive-compulsive disorder. *J Neural Transm*, 112:1115-29.

Crespo-Facorro B, Cabranes JA, Lopez-Ibor AI, et al. (1999) Regional cerebral blood flow in obsessive-compulsive patients with or without a chronic tic disorder, A SPECT study. *Eur Arch Psychiatry Clin Neurosci*, 249:156-161.

Denkla MB. (1985) Revised neurological examination and subtle signs. *Psychopharmacol Bull*, 21:773-779.

Diler RS, Kibar M, Avci A. (2004) Pharmacotherapy and regional cerebral blood flow in children with obsessive-compulsive disorder. *Yonsei Med J*, 45:90-9.

Ernst M, Liebenauer LL, King AC, et al. (1994) Reduced brain metabolism in hyperactive girls. *J Am Acad Child Adolesc Psychiatry*, 33:858-868.

Giedd JN, Rapoport JL, Garvey MA, et al. (2000) MRI assessment of children with obsessive-compulsive disorder or tics associated with streptococcal infection. *Am J Psychiatry*, 157:281-3.

Gilbert AR, Moore GJ, Keshavan MS, et al. (2000) Decrease in thalamic volumes of pediatric patients with obsessive-compulsive disorder who are taking paroxetine. *Arch Gen Psychiatry*, 57:449-56.

Goyette CH, Conners CK, Ulrich RF (1978) Normative data on revised Conners' parent and teacher rating scales. *J Abnorm Child Psychol*, 6:221-36.

Insel TR (1992) Toward a neuroanatomy of obsessive-compulsive disorder. *Arch Gen Psychiatry*, 49:739-744.

O'Tuama LA, Dickstein DP, Neeper N, et al. (1999) Functional brain imaging in neuropsychiatric disorders of childhood. *J Child Neurol*, 14: 207-221.

Öner Ö, Öner P, Aysev A, et al. (2005) Regional cerebral blood flow in children with ADHD: changes with age. *Brain Dev*, 27:279-85.

Pauls DL, Alsobrook JP, Goodman W, et al. (1995) A family study of obsessive-compulsive disorder. *Am J Psychiatry*, 125: 76-84.

Perani D, Colombo C, Bressi S, et al. (1995) [18F]FDG PET study in obsessive-compulsive disorder. A clinical/metabolic correlation study after treatment. *Br J Psychiatry*, 166:244-50.

Rosenberg DR, Keshavan MS (1998) Toward a neurodevelopmental model of obsessive-compulsive disorder. *Biol Psychiatry*, 43:623-40.

Rubia K, Overmeyer S, Taylor E, et al. (2000) Functional frontalisation with age: mapping neurodevelopmental trajectories with fMRI. *Neuroscience and Biobehav Rev*, 24:13-9.

Saxena S, Brody AL, Maidment KM, et al. (1999) Localized orbitofrontal and subcortical metabolic changes and predictors of response to paroxetine treatment in obsessive-compulsive disorder. *Neuropsychopharmacol*, 21:683-93.

Scahill L, Riddle MA, McSwiggin-Hardin M, et al. (1997) Children's Yale-Brown Obsessive Compulsive Scale: reliability and validity. *J Am Acad Child Adolesc Psychiatry*, 36:844-52.

Spalletta G, Pasini A, Pau F, et al. (2001) Prefrontal blood flow dysregulation in drug naïve ADHD children without structural abnormalities. *J Neural Trans*, 108:1203-1216.

Swedo SE, Pietrini P, Leonard HL, et al. (1992) Cerebral glucose metabolism in childhood-onset obsessive-compulsive disorder, revisualization during pharmacotherapy. *Arch Gen Psychiatry*, 49:690-4.

Şener S, Dereboy C, Dereboy IF, et al. (1995) Conners Öğretmen Derecelendirme Ölçeği Türkçe uyarlaması-1. *Çocuk ve Ergen Ruh Sağlığı Dergisi* 2: 131-141.

Yücelen A, Arman V, Topçuoğlu G et al. (2000) Çocuklar için Yale-Brown obsesif kompulsif geçerlik ve güvenilirlik değerlendirmesi. Poster presentation at 10. Ulusal Çocuk ve Ergen Kongresi, Sangerme.

Zametkin AJ, Liebenauer LL, Fitzgerald GA, et al. (1993) Brain metabolism in teenagers with attention-deficit hyperactivity disorder. *Arch Gen Psychiatry*, 50:333-40.

Zametkin AJ, Nordahl TE, Gross ME, et al. (1990) Cerebral glucose metabolism in adults with hyperactivity of childhood onset. *N Eng J Med*, 323:1361-1366.