

Mania Associated with Usher Syndrome Type II

ARTICLE IN PRESS

Samir Kumar PRAHARAJ¹, Mahima ACHARYA², Arul SARVANAN³, Sreejayan KONGASSERI⁴,
Rishikesh V. BEHERE⁵, P.S.V.N. SHARMA⁶

SUMMARY

Usher syndrome (or Hallgren syndrome) is an autosomal recessive genetic disorder characterized by sensorineural deafness, retinitis pigmentosa, and variable vestibular deficit; Usher syndrome type II is the most common form. Various neuropsychiatric disorders have been reported to occur in those with Usher syndrome, including schizophrenia-like disorder, atypical psychosis, recurrent depressive illness, neurotic disorder, and mental retardation; however, bipolar disorder is not common in those with Usher syndrome.

Herein we describe a 30-year-old male with Usher syndrome type II that developed features indicative of a probable manic episode. The patient had complete remission of symptoms in response to treatment with olanzapine 20 mg d⁻¹. In persons with dual sensory impairment there are inherent problems with assessment and diagnosis is difficult due to their limited communication abilities. The diagnosis of Usher syndrome depends heavily on behavioral observation and disturbances in vegetative functions.

Keywords: Usher syndrome, sensorineural deafness, retinitis pigmentosa, mania

INTRODUCTION

Usher syndrome, also known as Hallgren syndrome, is a genetic disorder with autosomal recessive inheritance characterized by sensorineural deafness, retinitis pigmentosa, and variable vestibular deficit. In all, 3 clinical subtypes of Usher syndrome have been identified (Waldeck et al. 2001; Keats 2002). Usher syndrome type I is characterized by profound congenital deafness, prepubertal onset of progressive retinitis pigmentosa, vestibular dysfunction, and central nervous system (CNS) abnormalities. Usher syndrome type II is characterized by moderate-to-severe congenital deafness, adolescent onset of retinitis pigmentosa, and the absence of vestibular dysfunction. Usher syndrome type III is characterized by rapidly progressing auditory deterioration with complete hearing loss by early childhood, adolescent onset of retinitis pigmentosa, variable vestibular dysfunction, and unknown CNS abnormalities. The prevalence of Usher syndrome ranges between 3 and 10 individuals per 100,000 (Waldeck et al. 2001).

Neuropsychiatric disorders associated with Usher syndrome include schizophrenia-like disorder, atypical psychosis, recurrent depressive illness, neurotic disorder, and mental retardation (Hallgren 1959; Small and Desmarais 1966; Pandey et al. 1982; Mangotich and Misiaszek 1983; Chaudhury et al. 1994; Hess-Röver et al. 1999; Jumaian and Fergusson 2003; Wu and Chiu 2006; Rijavec and Grubic 2009). A PUBMED search supplemented with a manual search showed that there is only 1 report of bipolar disorder comorbid with Usher syndrome (Rao et al. 2010). Herein we describe a male patient with Usher syndrome that developed features indicative of a probable manic episode.

CASE REPORT

Mr. A, a 30-year-old single male, was born full term with congenital deafness to consanguineous parents. His motor and language milestones were delayed, and he had sub-average

Received: 01.07.2011 - Accepted: 08.02.2012

^{1,4,5}Assist Prof., ^{2,3}MD, ⁶Prof., Department of Psychiatry, Kasturba Medical College, Manipal, Karnataka, India.

Samir Kumar Praharaj MD, e-mail: samirpsyche@yahoo.co.in

intellectual and social functioning since childhood. He did not receive any formal training in sign language; hence, he communicated his needs via a crude sign language. He developed decreased vision at night (nyctalopia), which began at ~10 years of age and has progressed slowly. He is able to perform simple household tasks (cleaning and looking after the cattle) and self-care activities with little supervision. His older sister also has congenital deaf-mutism and mental retardation. There was no known history of any other psychiatric disorder in the family.

The patients presented with acute onset of behavioral change that began 20 d earlier, characterized by pervasive irritability in response to trivial matters, agitation, and decreased need for sleep. He repeatedly indicated to family members via his crude sign language that he wanted to get married and wanted to visit various temples. This behavioral change was a marked deviation from his pre-morbid behavior. Due to his intellectual and sensory disabilities it was difficult to perform a formal mental status examination or assessment using Young's Mania Rating Scale, and as such DSM-IV criteria, including grandiosity and flight of ideas, could not be elicited. Nonetheless, behavioral observation during his first week of hospitalization showed pervasive irritable mood and psychomotor agitation in the form of increased gesturing. He was also observed to wake from sleep 2 h before his usual time in the morning and wander around the ward. These clinical findings were consistent with symptoms of change in mood, psychomotor agitation, and decreased sleep, which have been described as criteria for the diagnosis of mania in persons with intellectual disabilities (Matson et al. 2007; Sturmey et al. 2010).

Physical examination showed facial dysmorphism, characterized by a flat nose and broad forehead (Figure). Ophthalmological examination showed pigmentary changes in both retinas and high myopia, as well as cataractous changes in the right eye. Audiometric evaluation indicated bilateral profound sensorineural hearing loss. There were no features suggestive of vestibular dysfunction. Neurocutaneous markers were not observed and detailed neurological examination did not reveal any other deficits. Laboratory investigations, including complete blood count, liver and renal function tests, blood sugar, and electroencephalogram, were normal. Based on the Vineland Social Maturity Scale, a moderate level of impairment in his adaptive functioning was noted.

Considering the possibility of a manic episode, olanzapine 10 mg d⁻¹ was initiated and was gradually increased to 20 mg d⁻¹. There was a significant reduction in the behavioral symptoms after 2 weeks of olanzapine treatment and he was discharged from the hospital. At the 1-month post-discharge follow-up he was symptom free and had not experienced any adverse events.

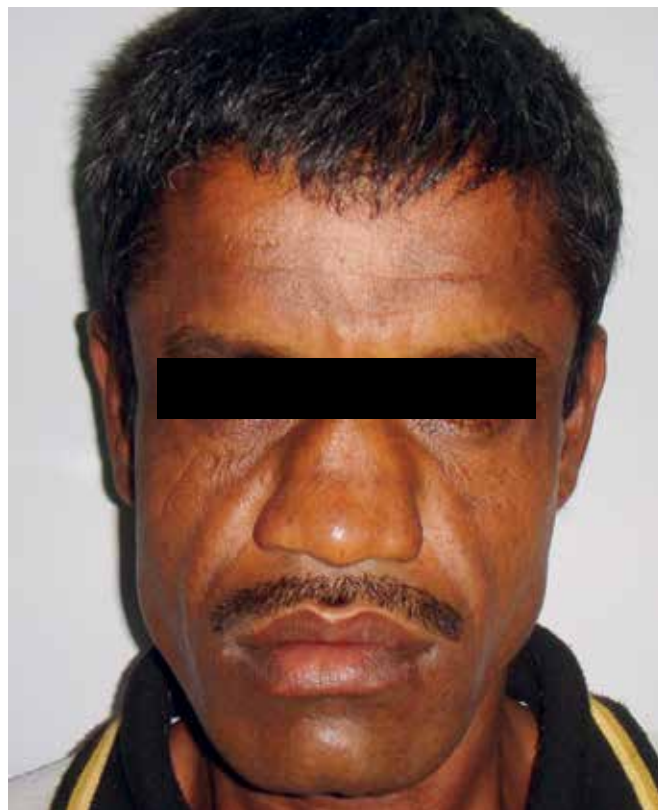


Figure. Dysmorphic facies.

DISCUSSION

In the presented case sensorineural deafness was present at birth and features of retinitis pigmentosa developed in late childhood, along with progressive visual loss, but there was no evidence of vestibular impairment. Additionally, mild-to-moderate mental subnormality was noted. The family history was suggestive of a similar disorder in a first-degree relative of the patient. These features were suggestive of Usher syndrome type II, which has been reported to be the most common form of Usher syndrome (Keats 2002). In contrast, Usher syndrome type I manifests with severe-to-profound sensorineural deafness, early-onset retinitis pigmentosa, and vestibular impairment (Smith et al. 1994; Tsilou et al. 2002), which was not evident in the presented case. Pigmentary retinopathy has been reported to be helpful in the diagnosis of Usher syndrome and differentiates it from other causes of non-syndromic sensorineural hearing impairment; night blindness is often reported as the initial symptom of retinal degeneration. Moreover, early onset of cataract was observed in the presented case, which conforms to the observation of Grondahl and Mjoen (1986), who reported that cataract was more common in patients with Usher syndrome aged >30 years. Nevertheless, genetic subtyping of Usher syndrome can be definitive, though it is not widely employed. To date, 9 different loci involved in Usher syndrome have been identified, and subtypes USH1B and USH2A account for 75%-80% of all cases (Yan and Liu 2010).

Although schizophrenia-like psychosis and unipolar depression has been frequently described in association with Usher syndrome, the association between Usher syndrome and bipolar disorder is not clear; only 1 such case (Rao et al. 2010) has been reported, in which the disease course was characteristic of bipolar disorder with multiple episodes, requiring a mood stabilizer in addition to antipsychotics. The presented case had a single episode suggestive of mania that responded to treatment with olanzapine with complete remission of symptoms.

The pathophysiology of psychosis in Usher syndrome is not known. Common genetic loci (Rao et al. 2010) and sensory deprivation (Hallgren 1959; Mangotich and Misiaszek 1983) have been reported to be contributory. Hallgren (1959) reported that the age of onset of the first psychotic episode in Usher syndrome patients correlated with the age at which visual impairment commonly becomes quite severe. Similarly, Mangotich and Misiaszek (1983) suggested there was a correlation between progressive sensory deprivation and psychotic symptoms in a patient with previously undiagnosed Usher syndrome. Several subsequent studies reported that sensory impairment, specifically when severe or multiple, as in Usher syndrome, results in higher rates of mental disorder, including psychosis (Hindley et al. 1994; Carvill 2001; Carvill and Marston 2002). Additionally, in late-life psychosis visual and hearing impairment are related to the severity of psychopathology, specifically when they are suboptimally corrected (Prager and Jeste 1993). In the presented case visual impairment was severe at the time of the onset of psychosis; as such, sensory deprivation due to both auditory as well as visual impairment might have contributed to its development. Furthermore, the genetic loci in Usher syndrome type II are reported to be 1q and 5q (Keats and Corey 1999). Interestingly, both of these chromosomal sites have also been implicated in linkage studies of bipolar disorder (Mirow et al. 1994; Turecki et al. 1995; Shink et al. 2002; Macgregor et al. 2004), which suggests a common genetic association between the disorders.

In persons with dual sensory impairment there are inherent problems with assessment and diagnosis is difficult due to their limited communication abilities, as in the presented case. Recent onset of behavioral changes, deterioration of socio-occupational functioning, and changes in neurovegetative signs are important clues to the existence of psychosis. As seen in the presented case, typical symptoms of mania, specifically manic cognitions, were difficult to establish. The diagnosis depended heavily on behavioral observation and disturbances in vegetative functions. It is imperative to have a high index of suspicion of psychosis when there is evidence of recent onset of changes in behavior in such patients, as it increases morbidity and impairment in socio-occupational functioning. As shown in the presented case, olanzapine, an atypical antipsychotic, can be safe and effective in the treatment of mania in patients with Usher syndrome.

REFERENCES

- Carvill S (2001) Sensory impairments, intellectual disability and psychiatry. *J Intellect Disabil Res*, 45: 467-483.
- Carvill S, Marston G (2002) People with intellectual disability, sensory impairments and behaviour disorder: a case series. *J Intellect Disabil Res*, 46: 264-72.
- Chaudhury S, Gurunadh VS, Singh GP et al. (1994) Hallgren's syndrome: two case reports. *Indian J Psychiatry*, 36: 193-4.
- Grondahl J, Mjoe S (1986) Usher's Syndrome in four Norwegian counties. *Clin Genet*, 30: 14-28.
- Hallgren B (1959) Retinitis pigmentosa combined with congenital deafness; with vestibulocerebellar ataxia and mental abnormality in a proportion of cases. A clinical and genetical study. *Acta Psychiatr Scand Suppl*, 138: 1-101.
- Hess-Röver J, Crichton J, Byrne K et al. (1999) Diagnosis and treatment of a severe psychotic illness in a man with dual severe sensory impairments caused by the presence of Usher syndrome. *J Intellect Disabil Res*, 43: 428-34.
- Hindley PA, Hill PD, McGuigan S, et al. (1994) Psychiatric disorder in deaf and hearing impaired children and young people: a prevalence study. *J Child Psychol Psychiatry*, 35: 917-34.
- Jumaian A, Fergusson K (2003) Psychosis in a patient with Usher syndrome: a case report. *East Mediterr Health J*, 9: 215-8.
- Keats BJ (2002) Genes and syndromic hearing loss. *J Commun Disord*, 35: 355-66.
- Keats BJ, Corey DP (1999) The Usher syndromes. *Am J Med Genet*, 89: 158-66.
- Koizumi J, Ofuku K, Sakuma K, et al. (1988) CNS changes in Usher's syndrome with mental disorder: CT, MRI and PET findings. *J. Neurol. Neurosurg. Psychiatry* 1988; 51: 987-90.
- Macgregor S, Visscher PM, Knott SA et al. (2004) A genome scan and follow-up study identify a bipolar disorder susceptibility locus on chromosome 1q42. *Mol Psychiatry*, 9: 1083-90.
- Mangotich M, Misiaszek J (1983) Atypical psychosis in Usher's syndrome. *Psychosomatics*, 24: 674-5.
- Matson JL, González ML, Terlonge C, et al. (2007) What symptoms predict the diagnosis of mania in persons with severe/profound intellectual disability in clinical practice? *J Intellect Disabil Res*, 51: 25-31.
- Mirow AL, Kristbjarnarson H, Egeland JA et al. (1994) A linkage study of distal chromosome 5q and bipolar disorder. *Biol Psychiatry*, 36: 223-9.
- Pandey RS, Sharma PSVN, Srinivasan K et al. (1982) Hallgren's syndrome: review of literature and two case reports. *Indian Journal of Psychological Medicine*, 30-3.
- Prager S, Jeste DV (1993) Sensory impairment in late-life schizophrenia. *Schizophr Bull*, 19: 755-72.
- Rao NP, Danivas V, Venkatasubramanian G et al. (2010) Comorbid bipolar disorder and Usher syndrome. *Prim Care Companion J Clin Psychiatry*, 12: PCC.09100792.
- Rijavec N, Grubic VN (2009) Usher syndrome and psychiatric symptoms: a challenge in psychiatric management. *Psychiatr Danub*, 21: 68-71.
- Shink E, Morissette J, Villeneuve A et al. (2002) Support for the presence of bipolar disorder susceptibility loci on chromosome 5: heterogeneity in a homogeneous population in Quebec. *Prog Neuropsychopharmacol Biol Psychiatry*, 26: 1273-7.
- Small JG, Desmarais GM (1966) The familial occurrence of retinitis pigmentosa, mental disorders, and EEG abnormalities. *Am J Psychiatry*, 122: 1286-9.
- Smith RJ, Berlin CI, Hejtmancik JF et al. (1994) Clinical diagnosis of the Usher syndromes. *Usher Syndrome Consortium*. *Am J Med Genet*, 50: 32-8.
- Sturmeijer P, Laud RB, Cooper CL, et al. (2010) Mania and behavioral equivalents: a preliminary study. *Res Dev Disabil*, 31: 1008-14.
- Tsilou ET, Rubini BI, Caruso RC et al. (2002) Usher syndrome clinical types I and II: could ocular symptoms and signs differentiate between the two types? *Acta Ophthalmol Scand*, 80: 196-201.
- Turecki G, Smith M, Mari JJ (1995) Type I bipolar disorder associated with a fragile site on chromosome 1. *Am J Med Genet*, 60: 179-82.
- Wu CY, Chiu CC (2006) Usher syndrome with psychotic symptoms: two cases in the same family. *Psychiatry Clin Neurosci*, 60: 626-8.
- Yan D, Liu XZ (2010) Genetics and pathological mechanisms of Usher syndrome. *J Hum Genet*, 55: 327-35.